

Localization of Multiple Pancreatic Insulinoma by Intra-arterial Calcium Stimulation with Hepatic Venous Sampling and Intra-operative Ultrasound Imaging: a Case Report

General ER^a, Cunanan EC^a, Uy JD^a, Crisaldo AS^a, Fiemtebella CJV^b, Navarro NS Jr^d, Tingcungco AG^c, Lopez RA^d, Mercado-Asis LB^b

^a Section of Endocrinology & Metabolism, ^b Departments of Surgery, ^c Interventional Radiology & ^d Pathology, University of Santo Tomas Hospital, Manila, Philippines

Insulinoma is a rare neuroendocrine tumor with an incidence of approximately 4 per 5 million population. They are typically sporadic, solitary and less than 2 cm in diameter. Despite the introduction of sophisticated cross-imaging techniques such as CT scan, MRI and ultrasound, localization of insulinomas, especially those smaller than 2 cm remains a problem; for this, one can localize insulinoma by stimulating release of insulin using selective intra-arterial injection of calcium and subsequent measurement of insulin levels in the hepatic veins. We report here a case of multiple pancreatic insulinomas measuring 3.0 x 2.1 x 2.0 cm (head) and 1.0 x 0.8 x 0.3 cm (body) not seen by imaging techniques but localized by intra-arterial calcium stimulation with hepatic venous sampling and intraoperative ultrasound imaging. This is the first selective intra-arterial calcium stimulation with hepatic venous sampling for localization of pancreatic insulinoma in the Philippines.

Key Words: Multiple, Insulinoma, Calcium Stimulation, Venous Sampling, Ultrasound

Received: 17.06.2007 Accepted: 24.10.2007

Correspondence: Edbert General, Department of Medicine, University of Santo Tomas Hospital, Espana, Manila, Philipines
E-mail: edbertgeneralmd@yahoo.com

Introduction

Insulinomas are functional neuroendocrine tumors of pancreatic beta islet cells with an estimated incidence of 4 cases / million persons per year, accounting for over 60% of all pancreatic islet cell tumors. Approximately 90% of insulinomas are solitary and benign; 10-15% are usually multiple adenomas and are associated with MEN.¹ The majority of patients diagnosed with an insulinoma are between 30-60 years of age, with women accounting for 59%.^{2,3} Insulinoma is the most common cause of hypoglycemia resulting from endogenous hyperinsulinemia.⁴ They present with neuroglycopenic symptoms including anxiety, dizziness, lightheadedness, personality changes, unusual behavior, confusion, incoherence, blurred vision, seizures and coma. Sympatoadrenal signs and symptoms such as palpitations, tremulousness, diaphoresis and tachycardia are due to catecholamine release in response to low serum glucose levels.⁵ Hypoglycemia and neuroglycopenic symptoms with subsequent measurement of insulin and insulin re-

lated components remain the major maneuver used in the diagnosis of hyperinsulinemic hypoglycemia.⁶ After biochemical diagnosis has been established, tumor localization is recommended because the successful resection is facilitated by precise preoperative localization. The majority of insulinomas are small and pose a challenge to even the most sophisticated imaging technology.

Preoperative localization of insulinoma using conventional imaging modalities such as ultrasonography and computed tomography have been disappointing with identification of only 20-50% of tumors.^{1,6} The sensitivity of MRI for detection of primary pancreatic tumor diminishes, however, with decreasing tumor size from up to 100% in large tumors to 30% when diameters are under 2 cm.⁷ Somatostatin-receptor scintigraphy has been used in the detection of neuroendocrine tumors.⁸ Unfortunately, half of the insulinomas do not express somatostatin receptors and the sensitivity, at best, reaches to only 60%. Based on these facts, hence emerge the more invasive modalities such as angiography, with intra-arterial calcium stimulation with hepatic venous sampling.

Case report

A. Clinical features: A 21 year-old female who presented with a two-year history of weakness, lightheadedness and diaphoresis upon waking up and during strenuous activities, symptoms relieved with food intake. She had two emergency room admissions because of loss of consciousness, then regained after administration of intravenous dextrose. Weight-wise, she had gained about 20-kg over the past two years. She reported no intake of sulfonylureas, use of steroids or injections of insulin. Her menstrual history was unremarkable. There was no one in the family with hypoglycemic events, or pituitary, pancreatic or parathyroid tumors. Her body mass index was 36 kg/m²; she had no acanthosis nigricans and was not cushingoid. She

had an adult type tanner stage of puberty. No nipple discharge was noted, and her abdomen was soft with no palpable masses or organomegaly. Neurological examination was also quite unremarkable.

B. Hormonal work-ups: A 72-hour fasting protocol is a major maneuver used in the diagnosis of hyperinsulinemic hypoglycemia state such as Insulinoma. In this test, the patient fasts for up to 72 hours under close medical supervision. When patient develops hypoglycemia defined as plasma glucose below 40 mg/dL accompanied by neuroglycopenic symptoms, serum C-peptide and insulin levels are determined. Elevated levels (serum insulin level >6 uIU/mL and serum C-peptide >0.6 ng/mL) are 95-100% diagnostic of hyperinsulinemic hypoglycemic state such as that of insulinoma.⁹ The results of our patients 72 hour fasting protocol and the other differentials are detailed in Table 1.

She had hypoglycemia (capillary blood glucose of 32 mg/dL) with neuroglycopenic symptoms at the 4th hour of the test with serum insulin level of 102 uIU/mL and C-peptide value of 14.82 ng/mL. A diagnosis of hyperinsulinemic hypoglycemia, probably from the insulinoma was made.

C. Imaging procedures: Abdominal sonography was normal, CT scan showed only prominence of the uncinata process of the pancreas with no appreciable mass, and MRI revealed no definite abnormality.

D. Intra-arterial calcium stimulation with hepatic venous: Sampling: A technique was developed to localize insulinomas before surgery by stimulating the release of insulin using selective intra-arterial injections of calcium gluconate as a secretagogue and then measuring insulin levels in hepatic veins.

This procedure is reported to have 94% sensitivity for diagnosing insulinoma.¹⁰ We then proceeded with selective intra-arterial calcium stimulation with hepatic venous sampling. Catheters were positioned in the right and left hepatic veins through bilateral femoral venous punctures.

Table 1. Protocol for a 72-hour fasting result showed hyperinsulinemia during hypoglycemia suggestive of insulinoma

Diagnosis	Symptoms or signs	Plasma glucose (mg/dL)	Plasma Insulin (μ U/mL)	C-peptide (nmol/L)	Anti insulin anti-receptor Abs	IGF-2	B OH butyrate	SU/meglitinide screen	Insulin-Glucose Ratio
Normal	No	>40	<6	<0.2	-	N	>2.7	-	<0.3
Insulinoma test cell hyperplasia	Yes	<40	>6	>0.2	-	N	<2.7	-	>0.3
Factitious sulfonylurea/meglitinide	Yes	<40	>6	>0.2	-	N	<2.7	+	>0.3
Factitious Insulin	Yes	<40	<6	<0.2	-	N	<2.7	-	>0.3
Non-islet cell tumor	Yes	<40	<6	<0.2	-	-	<2.7	-	<0.3
Abnormal counter-regulation	Yes	<40	<6	<0.2	-	N	>2.7	-	<0.3
Autoimmune	Yes	<40	<6	<0.2	-	N	>2.7	-	<0.3
Patient (4th hour)	Yes	32	102	4.9	NA	NA	NA	NA	3.2

After catheterization of the femoral artery, the gastroduodenal, superior mesenteric, splenic and hepatic arteries were selectively cannulated. Presampling selective angiogra-

phy was performed by injecting non-ionic contrast agent into each artery. A "tumor blush" at the region of the head was noted (Fig. 1).

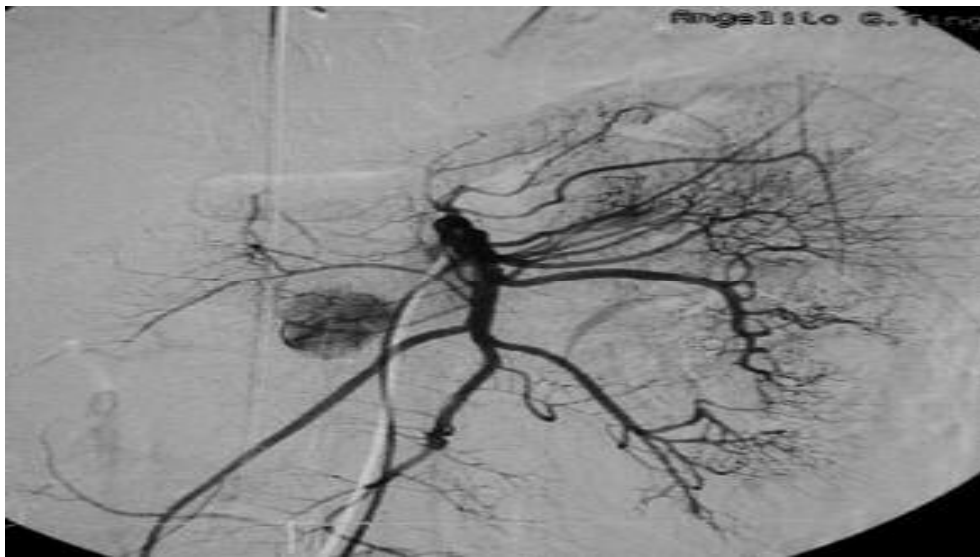


Fig. 1. Tumor blush seen at the region of the head of the pancreas during presampling selective angiography

Calcium gluconate (10% solution) at a dose of 0.025 meq Ca⁺⁺/kg was diluted to a 5 ml bolus and injected into each artery rapidly. Blood samples for insulin determination were obtained from both hepatic veins simultaneously at 0 and 30 seconds after calcium injection. An increase of more than 2-3 fold in insulin levels of hepatic venous samples, after injection to a feeding artery, was regarded as a positive response. A positive value into the splenic artery localized the tumor to the tail of the pancreas, into the mesenteric artery and gastroduodenal artery localized the tumor to the head and body.^{10,11} Our patient disclosed a three-to over five-fold rise of insulin level in both superior mesenteric (second zero: 52.87 uIU/mL and at 30 second post-calcium stimulation: 238.71 uIU/mL) and gastroduodenal arteries (0 sec: 109.8 uIU/mL, 30 sec post-calcium stimulation: 278.7 uIU/mL) implying the head and the body of the pancreas as the location of the tumor, (Fig. 2 & 3).

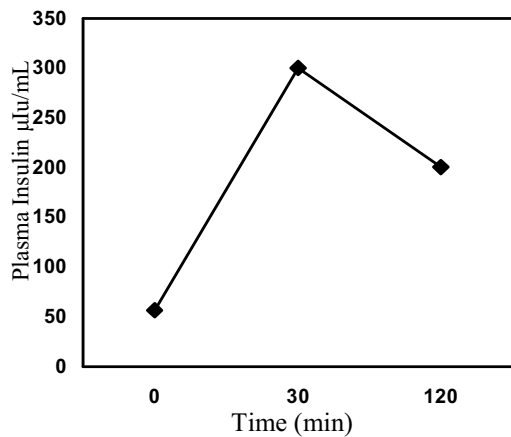


Fig. 2. Insulin levels during intraarterial calcium stimulation of superior mesenteric artery

Insulin gradients in splenic artery failed to rise after calcium stimulation (0 sec: 108.88–140.30 uIU/mL, 30 seconds post-calcium stimulation: 94.82–138.84 uIU/mL) indicating that pancreatic tail location of tumor to be unlikely. The results of her intra-arterial calcium stimulation test are detailed in Fig. 4.

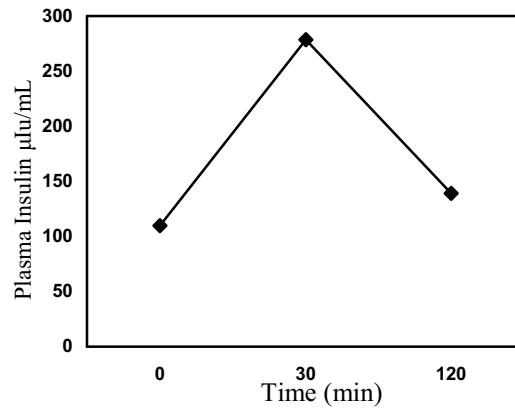


Fig. 3. Insulin levels during intra-arterial calcium stimulation of gastroduodenal artery

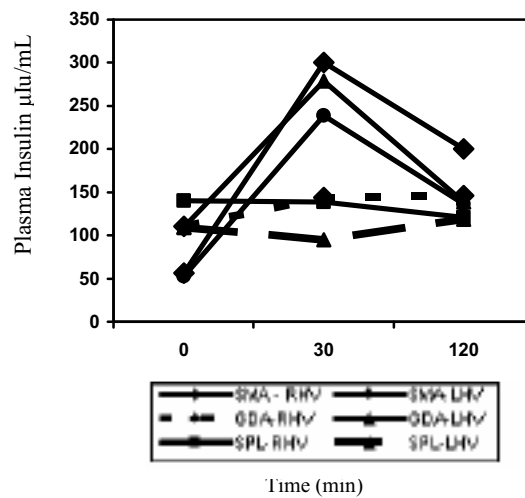


Fig. 4. Results of insulin level pre- and post- intra-arterial calcium stimulation test showing 3 to more than 5-fold elevation of insulin at the region of superior mesenteric artery (MSA) and gastroduodenal artery (GDA), implying tumors at the head and body regions of the pancreas. No insulin elevation was noted. SMA-superior mesenteric artery; GDA-gastroduodenal artery; SPL-splenic artery; RHV-right hepatic vein.LHV-left hepatic veinat the splenic artery (SPL)

E. Intraoperative ultrasound: The patient underwent exploratory laparotomy with intraoperative ultrasound revealing masses at the head (measuring 2.5×2.2 cm) and at the body (measuring 1.0×0.5 cm), Fig. 5.

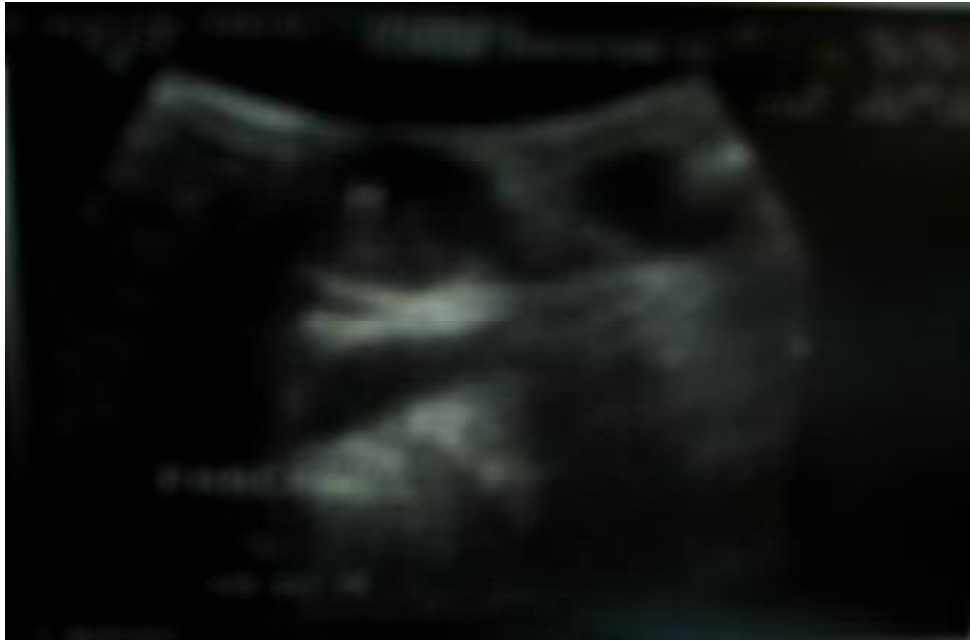

Fig. 5. Intraoperative ultrasound showing 2 solid nodules at the head and body of the pancreas

Enucleation of the masses was done; serial monitoring of her blood glucose and serum insulin levels are detailed in Fig. 6.

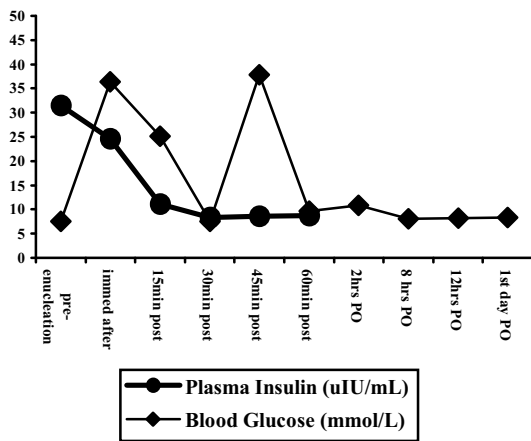


Fig. 6. Pre-, intra, and post-operative plasma insulin and glucose excursions. Note the normalization of both levels after enucleation

F. Histopathologic findings: Histologic section showed round to polyhedral cells which were pleomorphic with hyperchromatic nuclei with prominent nucleoli and irregular chromatin distribution and abundant eosinophilic granular to clear-out cytoplasm. Histopathology with chromogranin and synaptophysin staining revealed a pancreatic neuroendocrine tumor with blood vessel invasion (Fig. 7). K1-67 cells, staining showed less than 2% which signifies less aggressive behavior of the tumor.

G. Postoperative course: Postoperatively, her blood glucose was maintained at 80-120 mg/dL with normal serum insulin levels and no recurrence of hypoglycemia. The possibility of MEN was considered, in the light of multiple pancreatic insulinoma. Serum prolactin and calcium levels were normal.

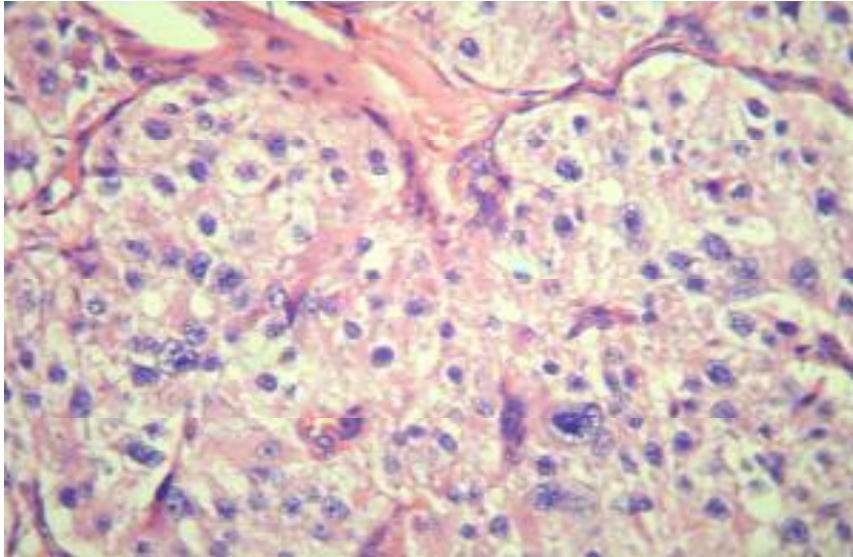


Fig. 7. Histological section of insulinoma showed round to polyhedral cells which are pleomorphic with hyperchromatic nuclei and prominent nucleoli with irregular chromatin distribution and abundant eosinophilic granular to cleared-out cytoplasm

Discussion

Considering the relatively poor and disappointing results obtained from conventional imaging, more invasive modalities have been attempted; angiography has been used many years. Insulinoma being hypervascular, appears as a “tumor blush” with contrast injection. The reported sensitivities are up to 72.2% at best, with use of digital subtraction angiography, but reach 100% when combined with intra-arterial calcium stimulation test.⁶ In vitro studies showed that a high extracellular calcium concentration invokes a rapid elevation of intracellular calcium concentration and an almost instantaneous increase in insulin release in insulinoma cells, regardless of glucose level, a finding not seen in normal pancreatic B cell lines. We then reported the very first selective intra-arterial calcium stimulation with hepatic venous sampling in the Philippines for localization of multiple pancreatic insulinomas. In situations where non-invasive imaging techniques failed to localize the tumor, additional attempts are recommended to identify a reli-

able localization tool to facilitate surgical resection is recommended. An exhaustive preoperative localization procedure may not be generally indicated because of the favorable outcome achieved by an experienced surgeon when a policy of careful bimanual palpation and intraoperative ultrasound is adopted. On the other hand, failure to resect a tumor because of an inability to localize it before surgery occurs in up to 10% of patients.^{11,12} A safe, sensitive preoperative localization procedure may facilitate a focused pancreatic exploration by an experienced surgeon. In addition, an accurate preoperative localization technique greatly improves patient confidence and allows for an informed discussion about the possible nature and the likely extent of surgery.¹²

Intra-arterial calcium stimulation with hepatic venous sampling for insulin gradients to localize the pancreatic insulinoma was first reported by Doppman et al in 1991. The sensitivity of the technique was 94% in the latest report on 35 patients with insulinoma.¹³ This is the most sensitive preoperative localization

method for insulinoma and has replaced portal vein sampling because of its simplicity, high sensitivity and relative non-invasiveness.

Our patient showed a three-to over five-fold increase in insulin levels in both superior mesenteric and gastroduodenal arteries, 30 seconds post calcium stimulation, implying the pancreatic head and body location of the tumors.

During exploratory laparotomy, intraoperative ultrasound showed two masses, each

at the head and body of the pancreas, facilitating a more focused and precise surgical resection of the tumors. These findings just showed us that a combination of preoperative intra-arterial calcium stimulation with hepatic venous sampling and intraoperative ultrasound are complementary to excellent approaches for localization and successful surgical resection of multiple pancreatic insulinomas.

References

1. Tso AW, Lam KS. Insulinoma. *Curr Opin Endocrinol Diabetes* 2000; 7: 83-88.
2. Lack EE, editor. *Pancreatic Endocrine Neoplasms*. New York: Oxford University Press 2003. p. 323-73.
3. Grant CS. Surgical aspects of hyperinsulinemic hypoglycemia. *Endocrinol Metab Clin North Am* 1999; 28: 533-54.
4. Radebold K. 2001. *Insulin e Medicine Journal* 2001 Volume 2 Number 11
5. Mittendorf EA, Liu YC, McHenry CR. Giant insulinoma: case report and review of the literature. *J Clin Endocrinol Metab* 2005; 90: 575-80.
6. Kuzin NM, Egorov AV, Kondrashin SA, Lotov AN, Kuznetsov NS, Majorova JB. Preoperative and intraoperative topographic diagnosis of insulinomas. *World J Surg* 1998; 22: 593-7
7. Phan GQ, Yeo CJ, Hruban RH, Lillemoe KD, Pitt HA, Cameron JL. Surgical experience with pancreatic and peripancreatic neuroendocrine tumors: review of 125 patients. *J Gastrointest Surg* 1998; 2: 472-82.
8. Lamberts SW, Bakker WH, Reubi JC, Krenning EP. Somatostatin-receptor imaging in the localization of endocrine tumors. *N Engl J Med* 1990; 323: 1246-9.
9. Hirshberg B, Livi A, Bartlett DL, Libutti SK, Alexander HR, Doppman JL, et al. Forty-eight-hour fast: the diagnostic test for insulinoma. *J Clin Endocrinol Metab* 2000; 85: 3222-6.
10. Doppman JL, Chang R, Fraker DL, Norton JA, Alexander HR, Miller DL, et al. Localization of insulinomas to regions of the pancreas by intra-arterial stimulation with calcium. *Ann Intern Med* 1995; 123: 269-73
11. Lo CY, Chan FL, Tam SC, Cheng PW, Fan ST, Lam KS. Value of intra-arterial calcium stimulated venous sampling for regionalization of pancreatic insulinomas. *Surgery* 2000; 128: 903-9.
12. O'Shea D, Rohrer-Theurs AW, Lynn JA, Jackson JE, Bloom SR. Localization of insulinomas by selective intraarterial calcium injection. *J Clin Endocrinol Metab* 1996; 81: 1623-7.
13. Brown CK, Bartlett DL, Doppman JL, Gordon P, Libutti SK, Fraker DL, et al. Intraarterial calcium stimulation and intraoperative ultrasonography in the localization and resection of insulinomas. *Surgery* 1997; 122: 1189-93.